



1 Indication

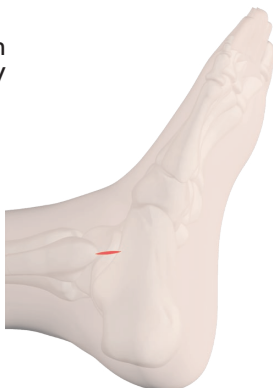Distal fibula fractures in geriatric patients.

2 Storage & Access

Positioning in supine position on normal table with free BV access.

Reduction by longitudinal traction using ligamentotaxis.

Skin incision (approx. 1.5 - 2.0 cm) from the outer tip of the ankle to the distal side.



Attention!

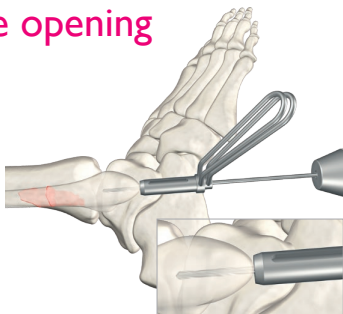
Risk of injury to the peroneal tendons if the incision is too deep!

3 Entry point

Determine the optimal entry point for the intramedullary guide wire using the image converter.

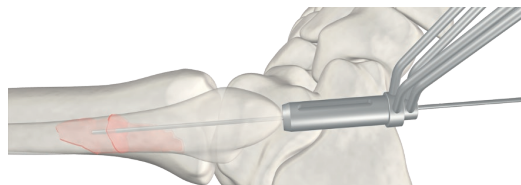
4 Medullary space opening

Set the drill guide system and ream the cortex using a Ø 2.5 mm drill. Image converter control during axial internal rotation of the lower leg.

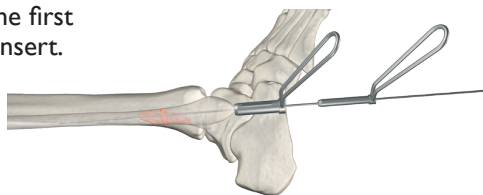


5 Positioning the guide wire

Insertion of the guide wire using the drill guide system.



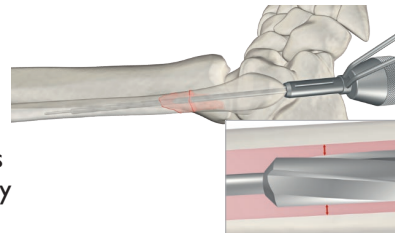
Removing the first drill sleeve insert.



6 Drilling the core diameter

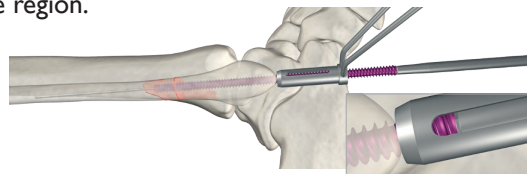
Ream the proximal narrow medullary canal to the core diameter of the screw using a cannulated drill Ø 3.5 mm through the tissue protection sleeve and over the guide wire. At the same time, we recommend using the drill under X-ray control to determine the appropriate screw diameter.

Tip!
Careful manual compression allows for better medullary cavity drilling.



7 Insertion of the screw

The screw is inserted through the tissue protection sleeve so as not to injure the skin surface by the sharp thread flanks. If necessary, manual compression of the fracture region.

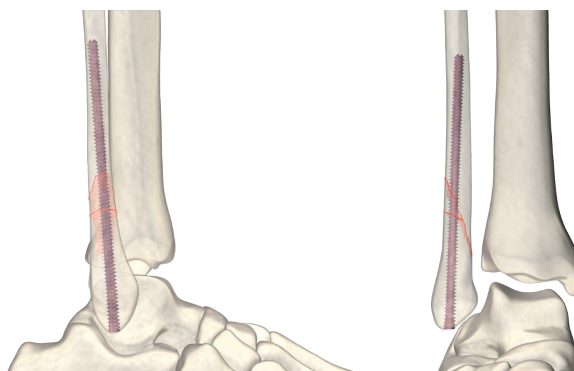
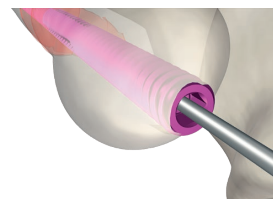


Tip!
With the help of the inspection hole in the tissue protection sleeve, a more precise determination of the position of the screw is possible.

8 Position control

Before removing the guide wire, a check is made in both planes.

The screw should at least be flush with the bone surface. If necessary, this can also be screwed in deeper.



This surgical technique is based on the author's many years of experience as a surgeon. Its content has been carefully considered and verified by the author. However, it cannot take into account all the specifics of the individual case and is therefore only a suggestion. All information in this surgical technique is therefore provided without any guarantee on the part of the author. No liability is assumed by the author for damages of any kind.




intercus

IntraOS

Overview of surgical technique

Größen Dimensions



Beschreibung Description

Ø		Artikel-Nr. Code N°	Farbe Colour	Name Name
5,5	S	S750.335840	Gold golden	IntraOS-Schraube, durchbohrt, selbstschneidend, selbstbohrend, für die Fixation bei distalen Fibulafrakturen bei geriatrischen Patienten IntraOS screw, cannulated, self-tapping, self-drilling, for fractures of the distal fibula in geriatric patients
6,0	M	S750.338840	Blau blue	
6,0	L	S750.347840	Hellgrün light green	
6,0	XL	S750.355840	Pink pink	
mm				<u>Material Material:</u> Ti6Al4V Ti6Al4V ISO 5832-3

Explantationsinstrumentarium Instruments for explantation

Sechskantschraubendreher, durchbohrt, für Drähte Ø 1,6 mm,
für Schrauben Ø 4,5 mm, Ø 5,5 mm, Griff
Cannulated hexagon screw driver, for wires Ø 1.6 mm,
for screws Ø 4.5 mm, Ø 5.5 mm, handle

Schlüsselweite Wrench size	Artikel-Nr. unsteril Code N° non-sterile
mm	
3,0	750.102056

